

Moebius Syndrome Misdiagnosed as Duane Retraction Syndrome: A Case Report

HARNOOR KAUR¹, NEHA K SETHI², HARSIMARPREET SINGH³



ABSTRACT

Moebius syndrome and Duane Retraction Syndrome (DRS) are Congenital Cranial Dysinnervation Disorders (CCDDs) characterised as congenital, non progressive groups of diseases caused by abnormal development of cranial nerve nuclei or their axonal connections. Due to their overlapping features, distinguishing between these disorders can be challenging, leading to potential diagnostic oversights. This is a case report of a 10-year-old female with Moebius syndrome misdiagnosed as DRS. She had 6th and 7th nerve palsies with exposure keratopathy. Probably the cause for misdiagnosis was the presence of an abduction deficit—a characteristic shared by both disorders. Additionally, it is crucial to examine the facial nerve, as it is exclusively affected in Moebius syndrome. DRS is significantly more common than Moebius syndrome; the rarity of Moebius syndrome might contribute to the misdiagnosis. Conducting a thorough examination is essential for differentiating between these conditions, thereby facilitating comprehensive management.

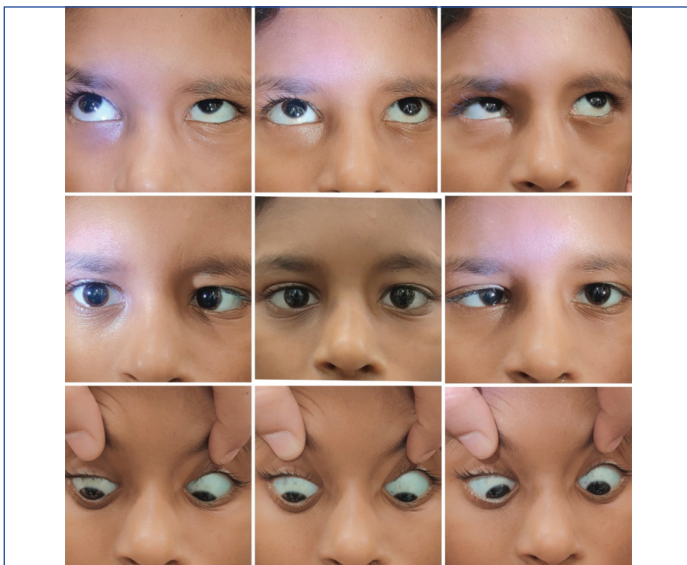Keywords: Congenital cranial dysinnervation disorders, Congenital facial palsy, Exposure keratopathy, Strabismus

CASE REPORT

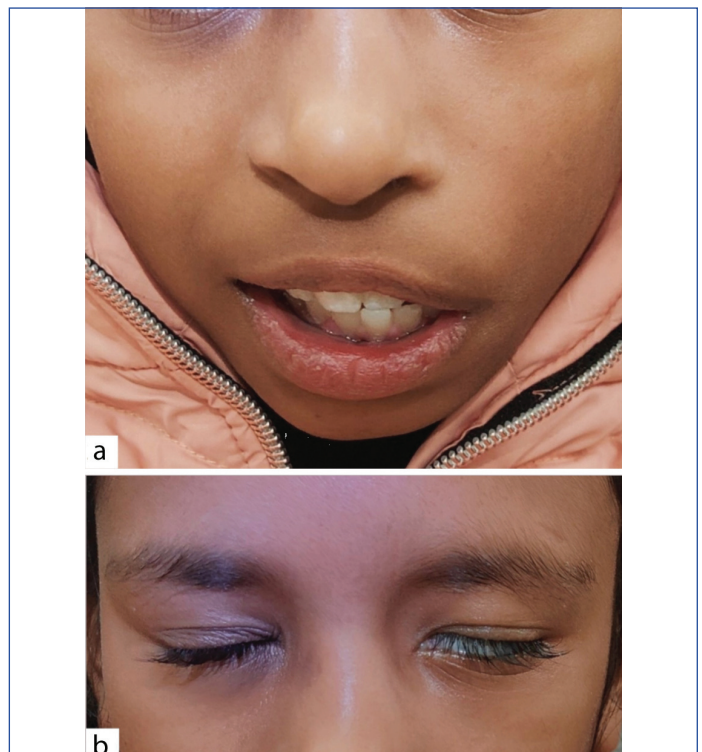
The 10-year-old female, diagnosed with left-eye (OS) DRS since five years, presented to the ophthalmology OPD for the first time with OS diminution of vision, watering, redness, and long-standing inability to close her left eye. The patient was systemically stable. There was no significant family or past history. Her Best Corrected Visual Acuity (BCVA) was 6/9 and 6/36 in the right eye (OD) and left eye (OS) respectively. OS had uncorrected hypermetropia of +2.75D with anisometropic amblyopia. The anterior segment examination was normal except in OS, showing Superficial Punctate Keratopathy (SPK). Intraocular pressure and fundus examination were normal in both eyes (OU).

OU abduction was restricted and suggestive of abducens nerve palsy; the visual axis was parallel in the primary gaze. Palpebral fissure height was the same in both abduction and adduction in both eyes; and importantly there was no globe retraction on adduction or abduction as shown in [Table/Fig-1]. OS had lagophthalmos, poor Bell's phenomenon, mild corneal exposure keratopathy, and

SPK on the cornea inferiorly in the left eye. She had a mask-like facial appearance. Examination of the seventh nerve revealed left facial palsy- no forehead furrows, no forehead wrinkling on the left-side, inability to close the left eye against resistance, deviation of the angle of the mouth to the right-side as shown in [Table/Fig-2]. The rest of the central nervous system, cranial nerve, and systemic examination were normal. The Magnetic Resonance Imaging (MRI) of her brain was also normal.



[Table/Fig-1]: Nine cardinal positions of gaze showing restriction in abduction and normal palpebral fissure height with no globe retraction.



[Table/Fig-2]: Tests of facial nerve were suggestive of left facial palsy: (a) Deviation of angle of mouth towards right-side with absence of the nasolabial fold on left-side of face while smiling; (b) Incomplete closure of left eye.

The diagnosis of the patient was revised as Moebius Syndrome as she had bilateral sixth and left seventh nerve palsy. She improved with medical treatment for exposure keratopathy including lubricants

(eyedrop carboxymethylcellulose 0.5%- QID), antibiotics (eyedrop moxifloxacin 0.5%-TDS), and night eye-taping. After one week of treatment, she had no SPK, decreased congestion, and vision improved to 6/24.

DISCUSSION

Authors report a case of Moebius syndrome (with OS facial and bilateral abducens palsy) misdiagnosed as OS DRS. Moebius syndrome is a congenital condition characterised by unilateral or bilateral facial and abducens nerve palsy with an incidence of 1 in 250,000; most often sporadic [1,2]. Patients suffering from this rare disease present with mask-like faces, deviation of the angle of the mouth, especially during smiling, lagophthalmos with or without exposure keratopathy, horizontal gaze palsies with intact vertical gaze, and normal palpebral fissure height with horizontal eye movements. It may also involve other cranial nerves, neurodevelopmental abnormalities of the limb and pectoral region, and autism [2].

On the other hand, DRS is a congenital complex strabismus with an incidence of 1 in 10,000; 10% of cases are familial [1]. It is characterised by a limitation of abduction or adduction of the eye (most commonly type 1 DRS with abduction limitation), retraction of the eyeball, and shortening of the palpebral fissure on attempted adduction due to co-contraction of horizontal recti [1,3].

Feature	Moebius syndrome	Duane retraction syndrome
Frequency	1 in 250,000; most often sporadic [1,2]	1 in 10,000; 10% cases familial [1]
Age at diagnosis	Often earlier (2-11 years) maybe due to mask like facies	Often in teens [6]
Overlapping symptoms and signs	Esotropia in primary gaze	Esotropia more in adduction but in severe cases in primary gaze also (in DRS Type-1)
Salient feature	Facial palsy due to 7 th nerve involvement; mask like facies, lateral rectus palsy	In 80% cases, abduction is limited (type 1), in 20% cases adduction or both adduction and abduction may be limited; globe retraction
Palpebral fissure height	No change in horizontal gazes	Narrowing on attempted horizontal eye movements.
Cranial nerve involvement	6 th and 7 th nerve most commonly involved Rarely-3 rd , 4 th , 9 th and 12 th	Aplasia of 6 th nerve nucleus and aberrant lateral rectus innervation by 3 rd nerve
Bilaterality	Facial nerve involvement- 97% bilateral [4]	Unilateral in upto 80% cases, often left-sided [3]
Abduction	Limited	Limited (in 80% cases)
Additional features	Developmental delay, musculoskeletal malformations, neurological disorders, mental retardation, problems with endocrine and respiratory system [8]	Other ocular findings- nystagmus, anisocoria, ptosis, congenital cataract, optic nerve hypoplasia Gustatory lacrimal reflex or crocodile tears.

[Table/Fig-3]: Summarises the differences between Moebius syndrome and Duane Retraction Syndrome (DRS) [1-4,6,8].

A major difference between Moebius syndrome and DRS is the presence of facial palsy in Moebius syndrome while the 7th nerve is unaffected in DRS. It is postulated that the cause of misdiagnosis was the abduction deficit in both eyes, which is a common feature of Moebius syndrome and type 1 DRS (the most common type). Additionally, the failure to determine the patient's facial nerve function, DRS being much more common than Moebius syndrome, and the probable ignorance of Moebius syndrome (which is rare) on the part of the previous treating ophthalmologist may have contributed to the misdiagnosis [4]. Also, although the vertical palpebral fissure height was constant in horizontal gazes, OS lagophthalmos was mistakenly interpreted as OD retraction in present case patient.

The management of both Moebius syndrome and DRS depends on the severity of squint. Strabismus surgery can help provide a parallel visual axis in at least the primary position with the surplus goal of improvement of visual motility in horizontal gazes. For Moebius syndrome, ocular management should additionally include prevention and treatment of exposure keratopathy due to associated 7th nerve palsy. Furthermore, support from a neurologist, paediatrician, plastic surgeon, counsellor, and physiotherapist is also required for managing the non ocular manifestations of the disease [5-7]. This latter aspect of management is likely to be neglected if such a misdiagnosis is made. [Table/Fig-3] summarises the differences between Moebius syndrome and DRS [1-4,6,8].

CONCLUSION(S)

Moebius syndrome (being a rare disorder) and DRS (relatively more common) may have overlapping clinical features, like abduction deficit. Therefore, a thorough examination, especially of facial nerve function, can help clinch the diagnosis and form the basis for comprehensive management of Moebius syndrome. The statement above reports a case of Moebius syndrome misdiagnosed as DRS.

REFERENCES

- [1] Gutowski NJ, Chilton JK. The congenital cranial dysinnervation disorders. Arch Dis Child. 2015;100:678-81.
- [2] Zaidi SMH, Syed IN, Tahir U, Noor T, Choudhry MS. Moebius syndrome: What we know so far. Cureus. 2023;15(2):e35187.
- [3] Gaballah KA, Shawky D. Treatment modalities in Duane's Retraction Syndrome. Int J Ophthalmol. 2020;13(1):278-83.
- [4] Assaf AA. Congenital innervation dysgenesis syndrome (CID)/congenital cranial dysinnervation disorders (CCDDs). Eye (Lond). 2011;25(10):1251-61.
- [5] Ali MH, Jamal S, Rashid MA, Javid U, Butt NH. Moebius syndrome with hypoglossal palsy, syndactyly, brachydactyly, and anisometropic amblyopia. Cureus. 2018;10(3):e2334.
- [6] Kekunnaya R, Gupta A, Sachdeva V, Krishnaiah S, Venkateshwar Rao B, Vashist U, et al. Duane retraction syndrome: series of 441 cases. J Pediatr Ophthalmol Strabismus. 2012;49:164-69.
- [7] Souni G, Ayad G, Elouali A, Babakhouya A, Rkain M. Moebius syndrome: a case report on an uncommon congenital syndrome. Cureus. 2023;15(6):e40746.
- [8] Chowdhury S, Sarkar S, Guha D, Dasgupta MK. Moebius syndrome: A rare entity or a missed diagnosis? J Pediatr Neurosci. 2020;15(2):128-31.

PARTICULARS OF CONTRIBUTORS:

1. Junior Resident, Department of Ophthalmology, Guru Gobind Singh Medical College and Hospital, Faridkot, Punjab, India.
2. Associate Professor, Department of Ophthalmology, Guru Gobind Singh Medical College and Hospital, Faridkot, Punjab, India.
3. Junior Resident, Department of Ophthalmology, Guru Gobind Singh Medical College and Hospital, Faridkot, Punjab, India.

NAME, ADDRESS, E-MAIL ID OF THE CORRESPONDING AUTHOR:

Dr. Neha K Sethi,
Department of Ophthalmology, Guru Gobind Singh Medical College and Hospital,
Faridkot-151204, Punjab, India.
E-mail: neha.knew@gmail.com

AUTHOR DECLARATION:

- Financial or Other Competing Interests: None
- Was informed consent obtained from the subjects involved in the study? Yes
- For any images presented appropriate consent has been obtained from the subjects. Yes

PLAGIARISM CHECKING METHODS: [Jain H et al.]

- Plagiarism X-checker: Jul 04, 2024
- Manual Googling: Jul 26, 2024
- iThenticate Software: Sep 09, 2024 (10%)

ETYMOLOGY: Author Origin

EMENDATIONS: 7

Date of Submission: Jul 03, 2024
Date of Peer Review: Jul 24, 2024
Date of Acceptance: Sep 10, 2024
Date of Publishing: Nov 01, 2024